

## **CLINICAL AND EPIDEMIOLOGICAL FEATURES OF HERPES ZOSTER IN KHORAZM**

Babajanov Khudaynazar Rajabovich  
Тма Urgench Branch, Senior Teacher Phd

### **Annotation**

Herpes zoster (HZ) is one of the common viral skin disease with typical clinical picture and well known etiology and pathogenesis. Epidemiological and clinical peculiarities and differences of herpes zoster in different ethnic groups and geographical regions still present a field of special interest.

**Keywords:** herpes zoster, incidence, epidemiology, epidemic situation, preventive measures, vaccination

### **Аннотация**

Работа посвящена изучению особенностей клинического течения опоясывающего герпеса (ОГ) в Харезмский области. К особенностям клинико-эпидемиологического характера ОГ в Харезмский области можно отнести доминирование среди больных городских жителей и довольно большой удельный вес тяжелых буллезно-геморрагических форм заболевания.

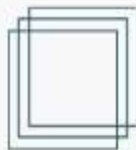
**Ключевые слова:** опоясывающий герпес, заболеваемость, эпидемиология, эпидемическая ситуация, профилактические мероприятия, вакцинация.

### **Introduction**

Herpes zoster is one of the most common dermatoses of a viral nature. Despite the typical clinical picture and the well-studied pathogenesis of the disease, there are often cases that present a clinical and therapeutic problem. The features and differences in the incidence of herpes zoster among residents of various ethnic groups and climatic and geographical regions remain insufficiently studied.

The topicality of the problem of herpes zoster (shingles) lies in its wide distribution in the world, high incidence rates in a significant part of the subjects of Kharezm, as well as the severity of complications caused by this infection.

The aim of the study was to analyze the epidemiological features of the incidence of herpes zoster in the territory of Kharezm.



Materials and methods. An epidemiological analysis of the incidence of herpes zoster in the territory of Kharezm was carried out using official statistics. Herpes zoster (herpes zoster, herpes zoster) is a viral disease of the skin and nervous tissue that occurs as a result of reactivation of the herpes virus type 3 and is characterized by inflammation of the skin and nervous tissue.

Human herpes virus type 3 (Varicella Zoster virus, Human herpesvirus, HHV-3, Varicella-zoster virus, VZV) - Alphaherpesviridae subfamily, Herpesviridae family.

The incidence of herpes zoster in various countries of the world is 1.5-3 cases per 10,000 people per year in all age groups and 7-11 per 10,000 per year in people over 60 years of age. The risk of developing OH in immunocompromised patients is 20-100 times higher. In children and adolescents, OH is rarely observed, cases of the disease of newborns whose mothers were ill with herpes zoster during childbirth are described.

Classification of a disease or condition (groups of diseases or conditions).

1. Shingles without complications:

- Erythematous phase;
- Vesicular form;
- Pustular form

2. Abortive form.

3. Hemorrhagic form.

4. Gangrenous form.

5. Generalized form.

6. Disseminated form.

7. Shingles with visual impairment.

8. Shingles with lesions of the oral mucosa, pharynx, larynx, auricle and auditory canal.

9. Herpes zoster complicated:

- Ophthalmic herpes;
- Hunt's syndrome.

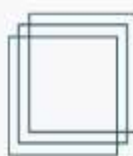
10. Shingles in children.

11. Herpes zoster in patients with HIV infection.

Results and discussion. A detailed clinical examination was carried out on 90 patients with herpes zoster (52 males and 38 females) aged 5 to 85 years, who were hospitalized in the clinic of skin diseases in Kharezm, who arrived from different regions. When evaluating the clinical variants of the development of herpes zoster, 57 (63.3%) patients had an erythematous-vesicular form of the disease, 19 (21.1%) had a hemorrhagic form, and 14 (15.6%) had a bullous form.

The vast majority of patients were over 50 years of age. The average duration of the disease in most patients at the time of visiting a doctor varied from 3 to 15 days in males and from 10 to 12 days in females.

When analyzing the place of permanent residence of patients with herpes zoster, it was found that the majority of patients (66.7%) were urban residents, less often the disease was recorded in rural residents (33.3%). An analysis based on professional employment showed that pensioners predominated among men - 44.2%) and persons involved in small business - 25%. Housewives

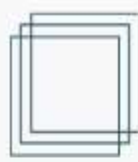


prevailed among women - 31.6% and pensioners - 26.3%. In 57 (63.3%) of the 90 examined patients, an erythematous-vesicular form of herpes zoster was observed, in 19 (21.1%) - hemorrhagic, in 14 (15.6%) - bullous. The distribution of patients according to the localization of herpetic eruptions is presented in the table. As can be seen from the table, rashes were more often localized on the skin of the trunk along the intercostal nerves and on the head along the branches of the trigeminal nerve (27.8%). In all patients, the initial period was manifested by prodromal symptoms: headache, malaise, subfebrile temperature, chills, dyspeptic disorders. At the same time, there was pain, a burning sensation, occasionally itching, as well as tingling and paresthesia along the peripheral nerve trunks in the area of future rashes. The duration of the initial period varied from 1 to 3-4 days, after which rashes appeared. Clinically, in the foci of patients with the erythematous-vesicular form of OH, slight swelling and erythema were observed, and against this background there were grouped, linearly located vesicles with serous contents.

In the hemorrhagic form of OH, edema with bright erythema was observed. Against the background of bright erythema and edema, there were many grouped vesicles, the diameter of the vesicles was 0.5 cm, the content was serous-hemorrhagic. Many vesicles, opening up, turned into erosions, then covered with hemorrhagic crusts. In the bullous form, in the lesions against the background of hyperemia and edema, there were many grouped vesicles and blisters with a tense cap, with a tendency to merge. Subfebrile temperature 2-3 days before the onset of the rash was observed in 72 (80%) patients. Herpetic eruptions in 5.6% of patients regressed after 1 week, in 85.5% after 9-12 days, in 8.9% after 20 days. The contents of vesicles and blisters were translucent in the first days, then became more cloudy. Patients with especially severe manifestations of herpes zoster, after discharge from the hospital, were recommended to conduct a comprehensive examination with an emphasis on cancer detection: ultrasound of the abdominal cavity, small pelvis, thyroid gland, prostate gland for men; X-ray of the chest, abdominal cavity, Turkish saddle; mammography; gastroduodenoscopy, colonoscopy; tumor markers of the digestive tract (total PSA, free PSA, CEA, SA 19-9).

A complete examination was performed in 15 of 33 patients with severe forms of herpes zoster. Oncological diseases were found in 9 patients: in men - lymphocytic leukemia in 1, stomach cancer in 2, intestinal cancer in 2, prostate cancer in 1; 2 women have breast cancer, 1 has lung cancer.

Thus, in Kharezm, herpes zoster is more often (57.7%) registered in older age groups; the incidence is higher among men (58.3%) than among women (42.7%). Urban residents get sick 2 times more often than rural residents (66.7% versus 33.3%). Clinically, erythematous-vesicular (64.4%), hemorrhagic (20%) and bullous (15.6%) forms of herpes zoster are more common, localized mainly on the skin of the trunk along the course of the thoracic nerves (55.8%). According to the results of a full-fledged oncological search conducted in 15 patients with severe OH, oncological diseases were diagnosed in 9 patients.



## References

1. Windham M. Herpes zoster. Attending physician. Russian Journal (Lechaschi Vrach Journal). 1999; 2-3: 3.
2. Leung A.K., Robson W.L., Leong A.G. Herpes zoster in childhood. J. Pediatr Health Care. 2006; 20(5): 303.
3. Mirzoeva M.T., Isaeva M.S. On the epidemiology of herpes zoster in Tajikistan in 2000-2011. Russian Journal of Skin and Venereal Diseases (Rossiyskii Zhurnal Kozhnykh i Venericheskikh Boleznei). 2014; 17(4): -P.50
4. Sapaeva D.N. Sadullayeva N.A Some Specific Features of Abbreviations using in Medical Terminology in English and Uzbek (On the Example of Dermatovenereological Vocabulary). Global Journals of Medical Research. Vol 20, No 7-K. 2020.  
<https://medicalresearchjournal.org/index.php/GJMR/article/view/2149>